

## Unerupted canine without median diastema

M. YAMAOKA, K. FURUSAWA, M. TANAKA & H. TANAKA *Oral and Maxillofacial Surgery Department II, Matsumoto Dental College, Shiojiri, Nagano, Japan*

---

**SUMMARY** The eruption of the canine is known to be a factor for diastema closure. In this study the relative changes in the orientation of the unerupted canine were assessed using the orthopantomographs of 9854 patients who sought consultation between April 1984 and March 1993. A total of 38 canines in 32 patients, all aged 11 years or older, were identified as unerupted canines. The features of the patients

with unerupted canine showed no significant relation to diastema closure status, but some patients had unerupted horizontal or inverted canine without diastema even in the absence of a history of orthodontic treatment, suggesting the presence of a mechanical force due to some phenomenon other than canine eruption as a factor in diastema closure.

---

### Introduction

Nowadays, median diastema is seen in children and rarely in adults. This disparity in frequency is linked to the eruption of the canines. The contribution of this phenomenon attributed to diastema closure is seen when the canine erupts within the arch in the normal direction (Weyman, 1967; Verluyten, 1989; Attia, 1993). However, we have encountered individuals with unerupted canines without diastema. It is apparent, therefore, that more than one factor is involved in diastema closure. We hypothesized that there might be other phenomena resulting in diastema closure after the eruption of the canines, and we therefore investigated radiographically the relationship between the diastema and unerupted canines in individuals more than eleven years of age.

The purpose of this report is to present data regarding the influence of the presence and angle of an unerupted canine on the diastema status.

### Materials and methods

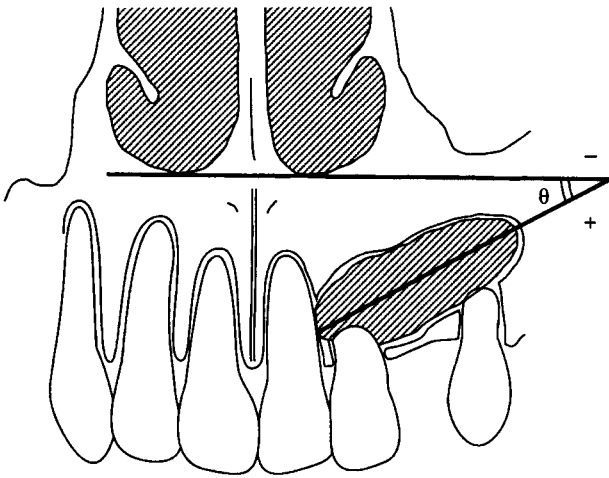
The material examined in this study consisted of the orthopantomographs of 9854 patients who had sought

consultation and care at our department of the Matsumoto Dental College between April 1984 and March 1993. Orthopantomographs were obtained with a Panoramax Auto I, 20 mA, 80-95KVP\* and the films were processed in an automatic developing machine†.

Only the orthopantomographs of subjects with unerupted canines aged 11 or more years were surveyed. Also excluded were patients with repaired or mesially decayed incisors, and those with trauma, anterior maxillary supernumerary teeth, missing premolars or molars without crown bridge repair, or with cleft palate. To acquire information regarding diastema closure, the subjects were interviewed regarding previous and present orthodontic treatment. Diastema was defined as a distinct separation between the crowns of the fully erupted maxillary bilateral incisors. Radiographically an unerupted canine was defined as one not located within the arch, despite the presence of completed root. The angle of the canine was measured on the orthopantomogram by calculating the differences between the angle formed by the tangent to the bilateral nasal floor and the long axis of the tooth (Fig. 1).

\*Asahi, Kyoto, Japan.

†Konica SRX-501, Konica, Tokyo, Japan.

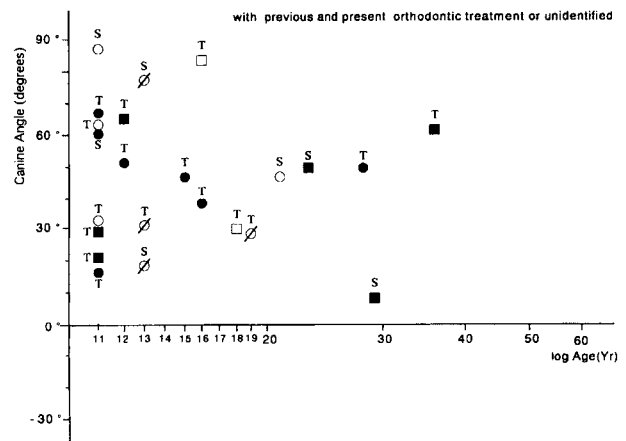
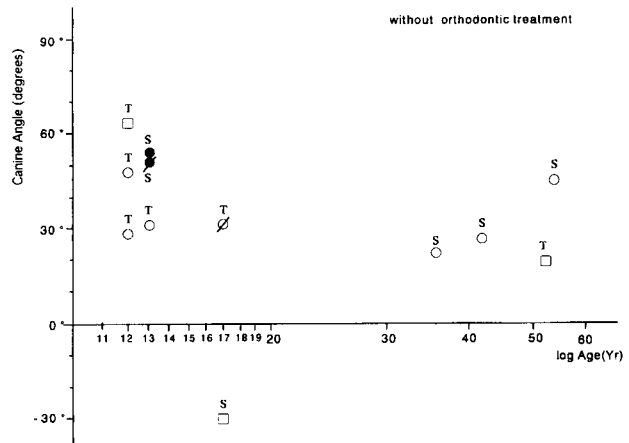


**Fig. 1.** In this study, the angle of the canine was measured in relation to the change in the angle  $\theta$ , as indicated in this sketch of an orthopantomogram. The angle  $\theta$  denotes the angle from the line through the bilateral nasal floor to the long axis of the canine.

All of the X-ray films were evaluated by one examiner, and the angle of the erupted canine, diastema, and root resorption of the incisors adjacent to the unerupted canine were recorded. The statistical methods used in the study included Fisher's exact test to determine significant differences.

**Results**

A total of 38 canines in 32 patients were identified radiographically as unerupted canines. All of the 12 males (11–52 years of age; mean age, 22.3 years) and 20 female (11–54 years of age; mean, 18.6 years) patients had all teeth from the central incisors to the bilateral second or third molars, though some also had a crown bridge for missing premolars or molars. Diastema was seen in 10 (45.4%) of the 22 subjects aged 11–20 years, and in 4 (40%) of the 10 subjects aged 21 years or more. There was no significant difference between the groups in the prevalence of diastema. When the patients were grouped according to whether they had a history of orthodontic treatment, those with and without such a history showed no significant difference in the incidence of median diastema (Fig. 2). No correlation was found between the angle of the canine and median diastema. Further grouping on the basis of root resorption also revealed no significant variation in the relationship between root resorption and diastema. However, there were three patients without diastema who had no history of orthodontic



**Fig. 2.** Canine angle versus age in the subjects without history of orthodontic treatment (above) and the subjects with history of orthodontic treatment or unidentified status (below). □, male without median diastema; ■, male with median diastema; ◐, male without median diastema but with incisor resorption; ◑, male with median diastema and incisor resorption; ○, female without median diastema; ●, female with median diastema; ◒, female without median diastema but with incisor resorption; ◓, female with median diastema and incisor resorption; S, subjects with second molars; and T, subjects with third molars.

treatment; these subjects were more than 30 years of age and had a canine angle of less than 35°.

**Discussion**

The subjects in this study did not include any with missing premolar or molar teeth not corrected with a crown bridge. The 44% incidence of diastema in the 32 subjects with an unerupted canine (selected among the total of 9854 patients) is significantly higher than that

reported in an Indian population-based study not limited exclusively to those with unerupted canine (160/9774; 1.6%) (Nainar & Gnanasundaram, 1989). Thus, the eruption of the canine clearly has a strong relation to diastema. Several previous reports have pointed out that the median diastema normally closes when the canines erupt (Weyman, 1967; Verluyten, 1989; Attia, 1993).

In this study, the diastema status was not found to show any significant variation associated with age, gender, canine angle or incision resorption. Perhaps this was due to the comparatively high variability in relation to the small number of patients. However, we found that some older patients who showed no diastema had no history of orthodontic treatment. This may indicate that they failed to seek treatment as a result of their dissatisfaction with the dental arch prior to spontaneous closure of the diastema. These findings may indicate that diastema closure is affected by the eruption of the second premolar, or the second or third molars, which occurs after the eruption of the canine, and that the incidence of diastema closure accordingly increases with age. Those patients with a horizontal impacted canine appear to have sufficient bone volume between the apices of the incisors and the nasal cavity and the maxillary sinus. Such malposition of the canine may lead to a closed diastema due to the mechanical force resulting from increased anterior movement of the posterior teeth. Our findings supported the concept of anterior movement of the molars that has been suggested by Hunter (1978) and Robertson, Cavina & Moss (1979). They noted that any determination of the amount of spacing must always be accompanied by consideration of the molar, canine and incisor interrelationships. If so, a horizontal unerupted canine may not be a risk factor for diastema and may be a

useful feature in the selection of patients for whom diastema closure might be beneficial, thus obviating unnecessary routine removal of the canine.

Resorption of root apices of the incisors was seen in patients aged 12–19 years. Direct mechanical force stimulation based on canine migration may cause resorption of the incisors at the root apices with slight bone volume of the alveolus. However, it was unclear whether this force is effective in diastema closure. On the other hand, the patients aged 20 or more years had no root resorption of the incisors. The movement of the canine toward the incisors accompanied by tooth resorption may indicate that removal of the canine and/or the incisors is warranted.

In conclusion, this study revealed no specific correlate of diastema. However, the likelihood of spontaneous diastema closure is suggested in a patient with horizontal impaction of the canines.

## References

- ATTIA, Y. (1993) Midline diastemas closure and stability. *Angle Orthodontist*, **63**, 209.
- HUNTER, W.S. (1978) Application of analysis of crowding and spacing of the teeth. *Dental Clinics of North America*, **22**, 563.
- NAINAR, S.M. & GNANASUNDARAM, N. (1989) Incidence and etiology of midline diastema in a population in south India (Madras). *Angle Orthodontist*, **59**, 277.
- ROBERTSON, N.A.E., CAVINA, R. & MOSS, J.P. (1979) The effects of the extraction of lower first premolars on the migration of teeth in the human dental arch. *Journal of Dental Research*, **58**, 1252.
- VERLUYTEN, P. (1989) Un diastème central au maxillaire. Une étude de cas. *Revue Belge de Médecine Dentaire*, **44**, 117.
- WEYMAN, J. (1967) The incidence of median diastemata during the eruption of the permanent teeth. *Dental Practitioner and Dental Record*, **17**, 276.

Correspondence: Professor M. Yamaoka, Oral and Maxillofacial Surgery Department II, Matsumoto Dental College, Shiojiri, Nagano 399-07, Japan.